

# Nursing role in early detection of cardiac amyloidosis: a case report

Noof Eid Saud Al shammari \*

RN, Nursing Specialist at Ministry of Health, Kingdom of Saudi Arabia, MSN student – Medical Surgical Nursing at King Abdulaziz University- Jeddah -Kingdom of Saudi Arabia

\*Corresponding author E-mail: [nsaudalshammari@stu.kau.ed.sa](mailto:nsaudalshammari@stu.kau.ed.sa)

## Abstract

Cardiac amyloidosis (CA) is a rare health condition that occurs due to amyloid deposits in the heart's tissues, it causes restrictive cardiomyopathy, which leads to heart failure and death. This report discusses a case of 72-year-old Saudi male known case of hypertension, diabetes mellitus, left ventricular dysfunction, and chronic kidney dysfunction presented to hospital with shortness of breath, paroxysmal nocturnal dyspnea, and orthopnea. Patient's physical examination revealed jugular vein distention, generalized pitting edema and abdominal distension. Echo image exhibited abnormal myocardial texture with moderate global hypokinesia, left ventricular D shape, and thickened interatrial septum. CA diagnosis is complex, and its diagnostic accuracy is relatively limited. Delay in CA diagnosis continues to challenge clinicians, which has adverse effects on patient's quality of life, and mortality rate. Underdiagnosis mainly because disease has nonspecific symptoms which often associated with poor prognosis. To aid in early diagnosis and treatment, nurses should be aware about symptoms, diagnostic approach, and disease progression of CA.

**Keywords:** Cardiac Amyloidosis; Early Detection; Nursing Role.

## 1. Introduction

Amyloidosis is a category of diseases marked by the unregulated accumulation of amyloid fibrils protein in several tissues in the body's organs (Gillmore et al., 2016). Many organs or organ systems as the heart, kidney, peripheral nerves, gastrointestinal tract, and eyes may be affected by the deposition of amyloidotic fibrils, which can cause structural and functional change. Cardiac amyloidosis is difficult to detect because the clinical manifestations are often varied and nonspecific (Gao et al., 2019). Patients with AL amyloidosis have 50% chance of cardiac involvement (Halwani et al., 2010). Amyloidosis is a rare systemic disease that affects people all over the world. The incidence is unknown, but AL amyloidosis, the most common condition, has an annual incidence of 6 to 10 cases per million in the United Kingdom and the United States (Banypersad et al., 2012). 50–65% of cases in this disease affect the heart, increasing patient morbidity and mortality (Agibetov et al., 2020).

There are subtypes of systemic amyloidosis; mainly three types cause severe cardiac disease (Shah et al., 2006). Primary amyloidosis is also known as AL amyloidosis or immunoglobulin light chain amyloidosis. It is the most popular and seems to be the worst prognosis (Picken, 2007; Gertz et al., 2005). AL amyloidosis could be associated with multiple myeloma which requires doses of chemotherapy to prevent severe complications after stem cell transplantation (Comenzo & Gertz, 2002). The secondary type of amyloidosis is mainly related to infectious or chronic inflammatory diseases, for example, rheumatoid arthritis (Picken, 2007). The third type is associated with hereditary and known as hereditary amyloidosis, which is related to a rare autosomal dominant trait (Cannon et al., 2004).

Given the accelerated deterioration seen in advanced stages of cardiac amyloidosis, an accurate and early efficient diagnostic approach in CA is critical and vital. In CA, it is well known that the onset of restrictive pathophysiology is associated with a significantly poor prognosis (Klein et al., 1991).

## 2. Case presentation

### 2.1. Medical history and chief complaints

Accelerated S.M. is a 72-year old Saudi male known case of hypertension and diabetes mellitus, non-ischemic cardiomyopathy, left ventricular dysfunction and chronic kidney disease. He presented to ER complaining of shortness of breath, difficulty in breathing when he is sleeping and lying down. He also reported that these symptoms had started over five weeks and progressed over time.

### 2.2. History of present illness

His medical history was notable for hypertension, diabetes mellitus, left ventricular dysfunction, non-ischemic cardiomyopathy, and chronic kidney dysfunction in the third stage.

### 2.3. History of past illness

He was diagnosed with hypertension and diabetes mellitus twelve years and ten years ago, respectively. He had also suffered from non-ischemic cardiomyopathy one year ago and chronic kidney diseases nine months ago. In 2018 he had coronary angiography. He was admitted to the hospital for four days six weeks before he complained of high blood pressure 189/120 mm Hg; he went through Discharge Against Medical Advice (DAMA) after mild improvement in his health condition.

### 2.4. Family/social history

The patient had a positive family history of hypertension and heart diseases. He lost his father 14 years before in heart failure, and his brother has hypertension. He also mentioned; as he has to visit his farm every day, he can't manage time for routine checkups and daily exercises. He usually consumes low salt, high carbohydrate, and fat diet and doesn't take adequate fruits & vegetables. In addition, he denied any history of smoking, alcohol, or drug abuse.

### 2.5. Medication history

The patient's pre-admission medications were Lasix (40 mg) orally BID, Metolazone (2.5 mg) orally OD on an alternative day, Aldactone (25 mg) orally OD, Perindopril (2.5 mg) orally OD, and Metformin (500mg) TDS orally and Aspirin (81mg) OD orally.

### 2.6. Physical examination upon admission

On admission, his vital signs were BP=172 /102 mm Hg, PR=83 bpm SPO2=92% Temp=36.8 °C, RR= 19 breaths per minute, Weight = 113 kg, Height= 170 cm. Tachypnea at rest using accessory muscle for breathing is noticed, chest dullness sound during percussion in the right side with decreased air entry. The patient had generalized pitting edema with massive scrotal swelling, elevated jugular venous pressure, abdominal distension with positive shifting dullness of liver, light peripheral cyanosis, and small white spots on fingernails. The protruding tongue was also noticed during CN XII Hypoglossal nerve assessment.

### 2.7. Laboratory examinations

After the patient was admitted to the hospital, a full blood profile test was done to check for any abnormalities. According to the protein electrophoresis report, Serum Alpha-1 globulin was 7.3 %, Kappa Light Chain free serum had a value of 82.9 mg/dl, total protein was 5.42 g/dl, protein/ creatinine ratio was = 821 mg/g creat, and total protein in urine was 32 mg/dl. The hematology report showed that platelet count was = 143 per microliter, and coagulation profile showed that PT= 14.9 seconds, PTT= 29.8 seconds, blood chemistry results showed that BUN=25.1 mg/dL, creatinine= 201 mmol/L, K=4.3 mmol/L, Uric acid= 604 μmol/L, Protein= 53.9 g/dL, Bilirubin= 7.4 g/L, Albumin= 32.8 g/L, Arterial Blood Gases results revealed respiratory acidosis PH= 7.493, pCO2= 54.4 mmHg and pO2= 73.9 mmHg.

### 2.8. Imaging examinations

ECHO revealed severe left ventricular systolic dysfunction with 25% ejection fraction, grade 2 diastolic dysfunction with high left ventricular filling pressure, abnormal myocardial texture with moderate global hypokinesia, and left ventricular D shape indicating pressure and volume overload with pulmonary hypertension. It also exhibited symmetrical severe concentric thickened AV and MV without significant valvular heart disease, trace tricuspid, large pleural effusion with mild trace, thickened interatrial septum, and brighter color indicates deposits of protein on the surface of the heart. (figure 1) (figure 2)

Electrocardiogram was done for the patient, and it showed slow cardiac rhythm, right bundle branch block, low voltage complexes QRS amplitude  $\leq 0.5$  mV in limb leads, and pseudo-infarct pattern (pathologic Q waves on leads V1 to V3), which indicate impaired of cardiac contractile function with amyloid infiltration. (figure 3)

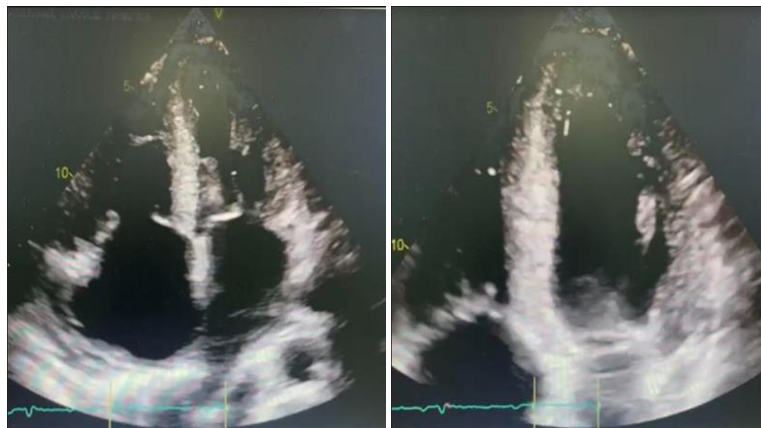
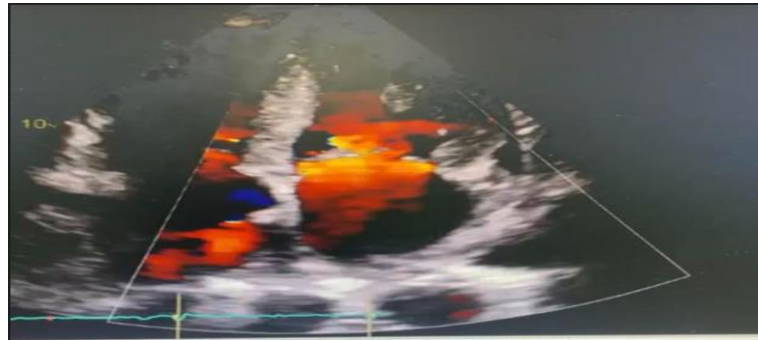
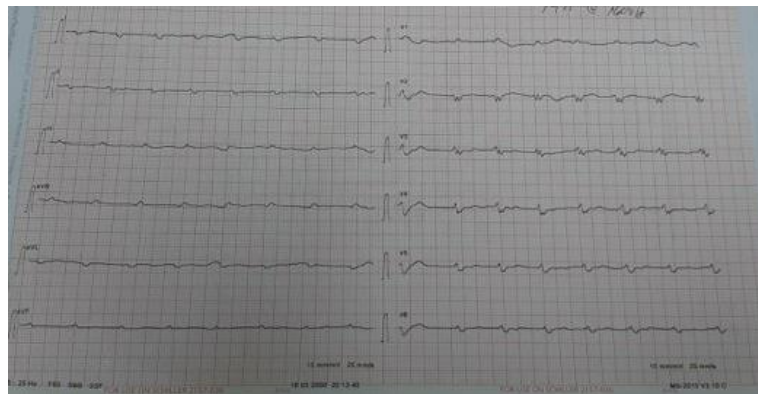


Fig. 1: Abnormal Myocardial Texture.



**Fig. 2:** Brighter Color Indicates Deposits of Protein on the Surface of the Heart.



**Fig. 3:** Electrocardiogram with Low Voltage in Limb Leads.

### 3. Treatment

On admission to CCU central venous catheter had been placed and following medications administered; Coversyl 5mg, Clexane 60mg, Concor 5mg, Heparin 5000IU, Ceftriaxone 2g, Gentamycin 500mg, Lasix 40mg, Metolzone 2.5mg, Aldactone 25mg, perindopril 2.5mg, omeprazole 20 mg, in addition to IV fluids.

As found in literature and previous studies that transplantation of heart in advanced stage of cardiac amyloidosis does not show good results due to frequent recurrence and possibility of amyloid deposition in donor's heart (Selvanayagam et al., 2007). Patient discharged after his condition had become stable within seven weeks of admission, in addition chemotherapy has recommended.

### 4. Outcomes

Outcomes among patients with cardiac amyloidosis improve with the continued development of novel AL and ATTR targeted therapies. The prognosis, mainly when diagnosed at an early stage, is now much improved compared with previous eras. Nonetheless, patients with advanced cardiac amyloidosis and those who fail to respond to disease-modifying therapy still have a poor prognosis and impaired quality of life. Early referral for palliative care support in this setting might be beneficial (Fine et al., 2020). In this case report, the patient was diagnosed with cardiac amyloidosis late-stage and had severe complications with unsatisfactory progress.

### 5. Follow-up

The patient is given a referral to the Hematology clinic for follow-up and referral to Oncology for follow-up and to start the doses of chemotherapy. Besides, the patient had given an appointment after one month with a Cardiologist and was advised to follow healthcare providers' instructions.

### 6. Discussion

Cardiac amyloidosis is a rare disorder where amyloid fibrils deposit in the heart's interstitium and causes morphological and functional anomalies. Since the clinical symptoms of cardiac amyloidosis are also varying and nonspecific, it is difficult to diagnose (Gao et al., 2019). Amyloid transthyretin (ATTR) amyloidosis and amyloid light-chain (AL) amyloidosis are the two main subtypes of cardiac amyloidosis. While there are many similarities in clinical signs and laboratory results between the disease forms, it is essential to distinguish them because their treatment and prognosis are different (Quarta et al., 2014).

Studies show that cardiac amyloidosis is underdiagnosed in the elderly population, and the prevalence rate is up to 25% in the age group of 80 and above (Mohammed et al., 2014; Cornwell et al., 1983). The classic clinical presentation of cardiac amyloidosis is associated with congestive heart failure signs like exertional dyspnea and orthopnea. Lethargy and fatigue are typical side effects of cardiac output deficiency. In certain patients, symptoms of right ventricular failure, such as abdominal distension and lower extremity edema, can be more noticeable. (Donnelly & Hanna, 2017; Bhogal et al., 2018). The thickening of the left ventricle wall is the most common echocardiographic feature, particularly in the absence of hypertension. Still, this feature has low specificity for the detection of cardiac amyloidosis. Echocardiographic characteristic of cardiac amyloidosis shows granular, sparkling, hyperechogenic appearance, which causes left ventricular hypertrophy. Moreover, its sensitivity tends to be low, at 26% to 36% (Selvanayagam et al., 2007).

Patients with CA-related heart failure have symptoms similar to those identified by patients with other heart failure phenotypes. Furthermore, the traditional screening instruments used to detect heart failure are no longer used (cardiac biomarkers, electrocardiographic markers, imaging techniques). Advanced expertise is needed to differentiate between amyloid and non-associated heart failure. Predictive algorithms based on advanced artificial intelligence techniques may be helpful in clinical diagnosis if they are included in this point. (Agibetov et al., 2020).

The gold standard for diagnosing cardiac amyloidosis is still a histological examination of endomyocardial tissue, though it has limitations. As a result, non-invasive diagnostic modalities for cardiac amyloidosis are needed. Echocardiography, ultrasound, and magnetic resonance imaging may reveal features that aren't always indicative of cardiac amyloid. In this context, nuclear medicine has developed several imaging modalities for diagnosis and prognostic stratification of cardiac amyloidosis (Noordzij et al., 2015).

A study conducted in 2020 among cardiologists considered the biopsy to diagnose patients with suspected heart failure, which is not standard practice (Mircsof, 2020). The time it takes for a diagnosis to be made harms cardiac function. A one-year delay was found to significantly negatively impact patients and cause mortality (Qian et al., 2014; Ruberg et al., 2012). Vascular issues, systolic and diastolic dysfunction, and conduction and rhythm disorders are functional effects of amyloid infiltration. A known complication of systemic amyloidosis is amyloidotic infiltration in the coronary arteries (Mueller et al., 2000).

Canadian Cardiovascular Society and Canadian Heart Failure Society Joint Position in 2020 had stated a recommendation that could be followed as a guidelines in order to early detect the cardiac amyloidosis, said as following:1) Diagnostic workup for cardiac amyloidosis for patients who present with signs and symptoms of heart failure who have one or more of the following features: (A) unexplained increased left ventricular wall thickness; (B) older than 60 years of age with left ventricular ejection fraction less > 40%; (C) unexplained peripheral sensorimotor neuropathy and/or dysautonomia; (D) history of bilateral carpal tunnel syndrome; and (E) established AL or ATTR amyloidosis, 2) performance of routine investigations for the evaluation of heart failure in patients who present with suspected cardiac amyloidosis, including 12-lead ECG, troponin, and BNP/NTproBNP,3) serum and urine protein electrophoresis with immunofixation assay be performed in all patients with suspected cardiac amyloidosis to evaluate for possible AL amyloidosis or other plasma cell dyscrasia (Fine et al., 2020)

## 7. Conclusion

Cardiac amyloidosis is a condition that is both fatal and progressive. To aid in early diagnosis and treatment, nurses should be aware of the symptoms of cardiac amyloidosis. Patients with early diagnosis and care have better results and a better quality of life. To understand cardiac amyloidosis, nurses must be familiar with the early signs and symptoms and disease progression. Nurses must protect patients from injury as weakness and syncope are common symptoms of amyloidosis, and they can put patients at risk of falling (Kendall, 2010). Guidelines for heart failure education may be adapted to teach patients with cardiac amyloidosis. Medication adherence and symptom management are critical components of heart failure patient education and contribute to the patient's overall quality of life (Edwardson, 2007).

## Acknowledgements

The author is gratefully acknowledge the colleagues Saif Al Rashidi,RN,MSN who helping in the this research.

## Funding

The author received no direct funding for this research

## Conflict of interest

None declared

## References

- [1] Agibetov, A., Seirer, B., Dachs, T., Koschutnik, M., Dalos, D., Retzl, R., Duca, F., Schrutka, L., Agis, H., Kain, R., Auer-Grumbach, M., Binder, C., Mascherbauer, J., Hengstenberg, C., Samwald, M., Dorffner, G., & Bonderman, D. (2020). Machine learning enables prediction of cardiac amyloidosis by routine laboratory parameters: A proof-of-concept study. *Journal Of Clinical Medicine*, 9(5), 1-11. <https://doi.org/10.3390/jcm9051334>.
- [2] Banyersad, S., Moon, J., Whelan, C., Hawkins, P., & Wechalekar, A. (2012). Updates in cardiac amyloidosis: A review. *Journal Of The American Heart Association*, 1(2), 1-10. <https://doi.org/10.1161/JAHA.111.000364>.
- [3] Bhogal, S., Ladia, V., Sitwala, P., Cook, E., Bajaj, K., Ramu, V., & Paul, T. K. (2018). Cardiac amyloidosis: an updated review with emphasis on diagnosis and future directions. *Current Problems in Cardiology*, 43(1), 10-34. <https://doi.org/10.1016/j.cpcardiol.2017.04.003>.
- [4] Cannon, J. D., Pullen, R. L., & Rushing, J. D. (2004). Managing the patient with amyloidosis. *Dermatology Nursing*, 16(3), 225.
- [5] Comenzo, R. L., & Gertz, M. A. (2002). Autologous stem cell transplantation for primary systemic amyloidosis. *Blood*, 99(12), 4276-4282. <https://doi.org/10.1182/blood.V99.12.4276>.
- [6] Cornwell III, G. G., Murdoch, W. L., Kyle, R. A., Westermarck, P., & Pitkänen, P. (1983). Frequency and distribution of senile cardiovascular amyloid: a clinicopathologic correlation. *The American Journal of Medicine*, 75(4), 618-623 [https://doi.org/10.1016/0002-9343\(83\)90443-6](https://doi.org/10.1016/0002-9343(83)90443-6).
- [7] Donnelly, J. P., & Hanna, M. (2017). Cardiac amyloidosis: An update on diagnosis and treatment. *Cleveland Clinic Journal of Medicine*, 84(12 Suppl 3), 12-26. <https://doi.org/10.3949/ccjm.84.s3.02>.
- [8] Edwardson, S. R. (2007). Patient education in heart failure. *Heart & Lung*, 36(4), 244-252. <https://doi.org/10.1016/j.hrtlng.2006.08.011>.
- [9] Fine, N. M., Davis, M. K., Anderson, K., Delgado, D. H., Giraldeau, G., Kitchlu, A., & Zieroth, S. (2020). Canadian cardiovascular society/Canadian heart failure society joint position statement on the evaluation and management of patients with cardiac amyloidosis. *Canadian Journal of Cardiology*, 36(3), 322-334. <https://doi.org/10.1016/j.cjca.2019.12.034>.
- [10] Gao, M., Liu, Q., & Chen, L. (2019). Cardiac amyloidosis as a rare cause of heart failure: A case report. *Medicine*, 98(14). <https://doi.org/10.1097/MD.00000000000015036>.
- [11] Gertz, M. A., Comenzo, R., Falk, R. H., Fermand, J. P., Hazenberg, B. P., Hawkins, P. N., Merlini, G., Moreau, P., Ronco, P., Santhorawala, V., Sezer, O., Solomon, A., & Grateau, G. (2005). Definition of organ involvement and treatment response in immunoglobulin light chain amyloidosis

- (AL): A consensus opinion from the 10th International Symposium on Amyloid and Amyloidosis. *American Journal Of Hematology*, 79(4), 320-324. <https://doi.org/10.1002/ajh.20381>.
- [12] Gillmore, J. D., Maurer, M. S., Falk, R. H., Merlini, G., Damy, T., Dispenzieri, A., & Hawkins, P. N. (2016). Nonbiopsy diagnosis of cardiac transthyretin amyloidosis. *Circulation*, 133(24), 2404-2412. <https://doi.org/10.1161/CIRCULATIONAHA.116.021612>.
- [13] Halwani, O., & Delgado, D. H. (2010). Cardiac amyloidosis: an approach to diagnosis and management. *Expert Review of Cardiovascular Therapy*, 8(7), 1007-1013 <https://doi.org/10.1586/erc.10.41>.
- [14] Kendall, H. (2010). Cardiac amyloidosis. *Critical care nurse*, 30(2), 16-23. <https://doi.org/10.4037/ccn2009202>.
- [15] Klein, A. L., Hatle, L. K., Taliercio, C., Oh, J. K., Kyle, R. A., Gertz, M. A., & Tajik, A. J. (1991). Prognostic significance of doppler measures of diastolic function in cardiac amyloidosis. A doppler echocardiography study. *Circulation*, 83(3), 808-816. <https://doi.org/10.1161/01.CIR.83.3.808>.
- [16] Mirsof, D. (2020). Diagnosis of amyloidosis: A survey of current awareness and clinical challenges among cardiologists in Switzerland. *Cardiology and Therapy*, 1-12. <https://doi.org/10.1007/s40119-019-00160-8>.
- [17] Mohammed, S. F., Mirzoyev, S. A., Edwards, W. D., Dogan, A., Grogan, D. R., Dunlay, S. M., Roger, V. L., Gertz, M. A., Dispenzieri, A., Zeldenrust, S. R., & Redfield, M. M. (2014). Left ventricular amyloid deposition in patients with heart failure and preserved ejection fraction. *JACC: Heart Failure*, 2(2), 113-122. <https://doi.org/10.1016/j.jchf.2013.11.004>.
- [18] Mueller, P. S., Edwards, W. D., & Gertz, M. A. (2000). Symptomatic ischemic heart disease resulting from obstructive intramural coronary amyloidosis. *The American Journal of Medicine*, 109(3), 181-188. [https://doi.org/10.1016/S0002-9343\(00\)00471-X](https://doi.org/10.1016/S0002-9343(00)00471-X).
- [19] Noordzij, W., Glaudemans, A. W., Longhi, S., Slart, R. H., Lorenzini, M., Hazenberg, B. P., & Rapezzi, C. (2015). Nuclear imaging for cardiac amyloidosis. *Heart Failure Reviews*, 20(2), 145-154. <https://doi.org/10.1007/s10741-014-9463-6>.
- [20] Picken, M. M. (2007). New insights into systemic amyloidosis: The importance of diagnosis of specific type. *Current Opinion in Nephrology and Hypertension*, 16(3), 196-203. <https://doi.org/10.1097/MNH.0b013e3280bdc0db>.
- [21] Qian, G., Wu, C., Zhang, Y., Chen, Y. D., Dong, W., & Ren, Y. H. (2014). Prognostic value of high-sensitivity cardiac troponin T in patients with endomyocardial-biopsy proven cardiac amyloidosis. *Journal of Geriatric Cardiology: JGC*, 11(2), 136.
- [22] Quarta, C. C., Solomon, S. D., Uraizee, I., Kruger, J., Longhi, S., Ferlito, M., & Falk, R. H. (2014). Left ventricular structure and function in transthyretin-related versus light-chain cardiac amyloidosis. *Circulation*, 129(18), 1840-1849. <https://doi.org/10.1161/CIRCULATIONAHA.113.006242>.
- [23] Ruberg, F. L., Maurer, M. S., Judge, D. P., Zeldenrust, S., Skinner, M., Kim, A. Y., Falk, R. H., Cheung, K. N., Patel, A. R., Pano, A., Packman, J., & Grogan, D. R. (2012). Prospective evaluation of the morbidity and mortality of wild-type and V122I mutant transthyretin amyloid cardiomyopathy: The transthyretin amyloidosis cardiac study (TRACS). *American Heart Journal*, 164(2), 222-228 <https://doi.org/10.1016/j.ahj.2012.04.015>.
- [24] Selvanayagam, J. B., Hawkins, P. N., Paul, B., Myerson, S. G., & Neubauer, S. (2007). Evaluation and management of the cardiac amyloidosis. *Journal of the American College of Cardiology*, 50(22), 2101-2110. <https://doi.org/10.1016/j.jacc.2011.02.008>.
- [25] Shah, K. B., Inoue, Y., & Mehra, M. R. (2006). Amyloidosis and the heart: a comprehensive review. *Archives of Internal Medicine*, 166(17), 1805-1813. <https://doi.org/10.1001/archinte.166.17.1805>.