



Surgical Management of Neurotuberculosis: Review of Radiological Spectrum

V K S Gautam^{1*} and Ravinder Singh²

¹*Department of Neurosurgery and* ²*Department of Medical Anthropology,
Institute of Human Behavior and Allied Sciences Hospital,
Faculty of Medical Sciences, University of Delhi,
GNCT Delhi, Dilshad Garden, Delhi -110095, India*
**Corresponding author E-mail: drvksg@rediffmail.com*

Abstract

Paper reviews the radiological findings of 31 patients of central nervous system tuberculosis (CNS TB) undergone the neurosurgical intervention. As the diagnosis of CNS TB poses a difficulty due to non specific clinical presentation, inability to retrieve microorganism or histopathological tissues, radiological investigations are useful in assessment, diagnosis and treatment of CNS TB. This review may serve as guide to clinicians for a practical approach in investigating cases of neurotuberculosis.

Keywords: *CT scan, MRI, Neurotuberculosis, X-Ray.*

1 Introduction

Tuberculosis (TB), in any form, is a devastating disease. When it involves the central nervous system (CNS) leads to high mortality and morbidity. Central nervous system tuberculosis (CNS TB) constitutes 5 to 10 percent of extra pulmonary tuberculosis cases and overall accounts for approximately one percent of all TB cases [1]. Therefore early diagnosis of CNS TB is necessary for appropriate treatment. Routine diagnostic techniques including culture and immunological tests of the tissue and bio-fluids often are time consuming and delay the diagnosis and management [2]. Radiological investigations have emerged as the most diagnostic tool in initiating treatment and follow up of CNS TB. Review of abnormalities as observed in Roentgenograms, CT scans and MR studies in thirty one surgically managed cases of CNS TB may evolve a pragmatic and evidence based diagnostic approach for surgical management of neurotuberculosis for clinicians.

2 Method

Thirty one patients of CNS TB underwent neurosurgery between March 2009 and March 2013. Their analysis is part of descriptive case series for radiological investigations- chest X-Ray, CT scan and MRI. Patients were included through non-probability convenience sampling in Neurosurgery OPD of neuropsychiatric hospital. Most of patients were sub acute or chronic and were operated by the first author. All the patients were investigated systematically through various diagnostic tests. Radiological investigations like X-Ray Chest, CT scan or MRI or both and in some case X- Ray skull or spine were done. According to the neurosurgical diagnosis and evidence based practice, neurosurgical procedure was done whenever required. The patients were assessed, both clinically and radiologically, in follow up for two years after neurosurgical interventions. Paper retrospectively reviews of the Roentgenograms, CT scans and MR studies of these patients. The data were entered, compiled and analysed in MS Excel and the statistical output was represented as frequencies and percentages of presenting complaints and clinical features (Table-1).

3 Results

The mean age of patients was 18 years, ranges from 6 months to 80 years. There were 14 male and 17 were female patients and none of them was immunocompromised. The mean duration of illness was 6 months ranging from minimum for 10 days to maximum for 4 years. There were 6 patients out of 31 patients with past history of tuberculosis.

Table 1: Diagnostic profile of the study group

Diagnosis	Patients (N=31)	Percentage (%)
Hydrocephalus	23	74
Potts's spine with cord compression	6	19
Spinal arachnoiditis*	2	6
Calvarial Tuberculosis with extradural lesion	2	6

(*1 patient of Pott's spine and 1 patient of hydrocephalus had associated spinal arachnoiditis)

Post tubercular hydrocephalus was most common clinical presentation in 23 (74%) cases. Ventriculo-peritoneal shunt (VP Shunt) surgery was common modality of treatment for obstructive hydrocephalus followed by 6 patients of Potts spine, one patient of Potts spine and hydrocephalus had associated spinal arachnoiditis. There were two cases of calvarial tuberculosis with intracranial extradural lesion. Chest X-Ray suggested pulmonary TB in 6 cases. Vertebral tuberculosis was most common in the thoracic region.

4 Discussion

The review of radiological investigations is divided into three sections- first, Roentgenograms; second, CT scans and third, MRI of thirty one surgically managed CNS TB cases as follows.

4.1 Roentgenogram (X-Ray) in CNS TB

X-Ray Chest, postero-anterior view (PA view), is advised for all the patients of CNS TB undergoing a neurosurgical procedure. Though, X-Ray chest may not be positive for pulmonary TB, however it is required for the pre-anesthetic check up (PAC) before surgery and anesthesia and in some cases it may reveal evidence of tubercular etiology. It is reported 20 to 60 percent of patients have shown positive X- ray chest radiograph [3,5]. In our study X-Ray chest of 6 patients (19 percent) had shown the features of pulmonary TB. X-Ray of craniovertebral junction (open mouth view, anteroposterior, lateral and neutral views) is required in patients with craniovertebral junction tuberculosis. If patient presents with a cold abscess of the scalp or a bony lesion or defect in the skull, X- ray skull anteroposterior view (Fig-1) and lateral view should be advised which may reveal a lytic lesion with irregular margins suggestive of tubercular osteomyelitis⁶. Skull X-ray should not be advised unless osteomyelitis of skull bone is suspected.

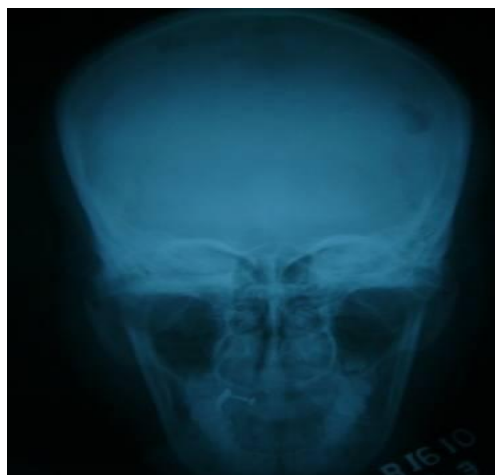

Fig. 1: Anteroposterior of skull showing a defect (lytic lesion) in the cranium suggestive of osteomyelitis.

In case of tubercular spine, the infection typically commences at the superior or inferior anterior vertebral body corner adjacent to the discovertebral junction and spreads by subligamentous extension and penetration of the subchondral plate. As disease progress, the lateral and anterior cortices of the vertebral body may destroy, leading near to collapse,

kyphosis and vertebral instability. Since the disk is avascular, disk infection appears late and results in disc interval narrowing secondary to herniation of the disk into the undermined, collapsed vertebral body. When two contiguous vertebral bodies are involved then nutrition of the disk is affected. Collapse and wedging of multiple vertebral bodies because of intraosseous cavitation result in the characteristic gibbus deformity. Less often, posterior elements of the spine may be involved [11]. The latter has been reported to occur characteristically in TB and is not observed in pyogenic infections of the spine [7, 8]. Involvement of the neural arch may occur either alone or in combination with vertebral body lesions⁹. Other atypical patterns of tuberculous involvement of the spine consist of infection of a single vertebra or multiple nonadjacent vertebrae ('skip lesions')[9,10]. In our analysis vertebral tuberculosis was most common in the thoracic region and this finding is consistent with other reported studies [11].

The plain radiography of tuberculous spondylodiscitis may demonstrate loss of vertebral height, disk space narrowing, and erosions of the end plates, paravertebral masses and soft tissue calcifications [10,11]. Plain radiography is not sensitive for the early detection of vertebral tuberculosis. Disk space narrowing may be quite subtle and vertebral involvement is not detected until half of the trabecular bone is damaged [10]. The X- ray of the spine, anterior-posterior and lateral view, is still relevant despite the advent of MRI. It should be done in all patients suspected to have tubercular spine as it helps to identify extent of bony involvement including collapse of vertebral body, kyphosis and any potential instability of spine. Bone scan should not be advised as a routine investigation for the diagnosis of CNS TB.

4.2 Findings of CT scan in CNS TB

Kumar et al. [12] reported CT scan criteria for the diagnosis of CNS tuberculosis and proposed that basal meningeal enhancement, tuberculoma, or both were 89% sensitive and 100% specific for TBM. CT Scan of the brain identifies basal meningeal enhancement, ventriculomegaly (Fig.-2A), tuberculoma and infarcts and may help in distinguishing CNS tuberculosis from other diseases.

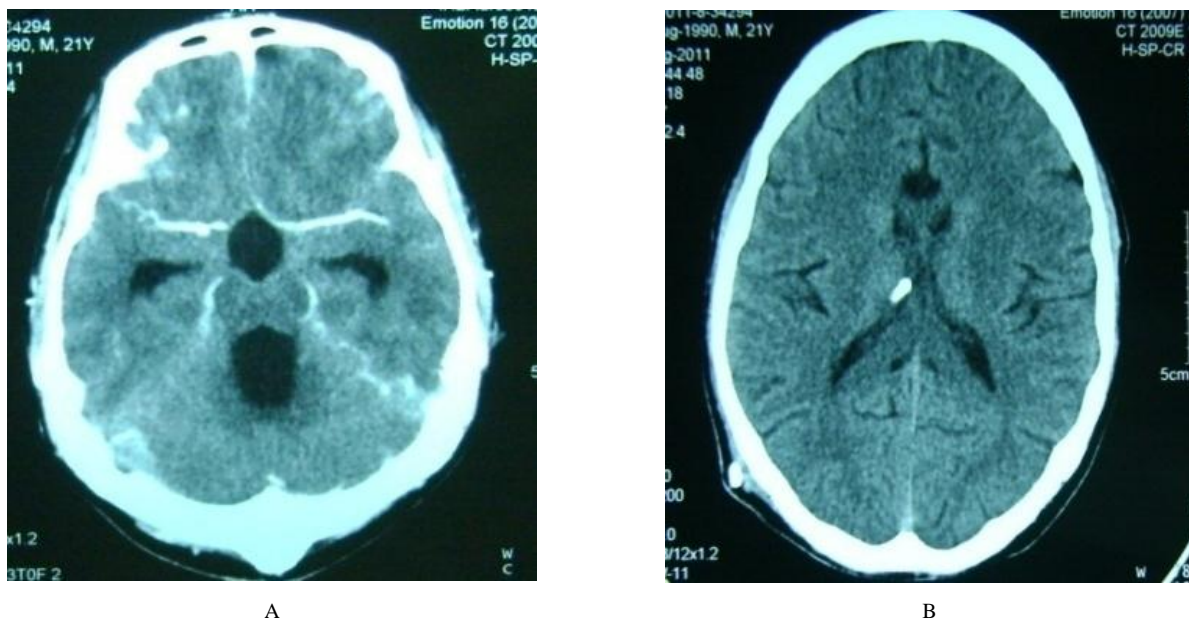


Fig.2: A - CT scan of brain with contrast axial views, showing meningeal enhancement and ventriculomegaly, B- Post op CT scan showing ventricular end of the VP shunt and normal ventricles and opened up cortical sulci and gyri.

CT scan is better for immediate post operative evaluation of the patient and reveals the ventricular tip position (Fig-2 B). It also detects any complication of the ventriculoperitoneal shunting *e.g.* development of intracranial hematoma. CT scan of the spine is sometimes required if the patient cannot undergo MRI due to claustrophobia or presence of pacemaker or ferromagnetic implant in the body. Abscess with calcification is diagnostic of spinal TB; CT is excellent modality to visualize soft tissue calcifications and it determines the pattern and severity of bony destruction. CT guided biopsy is another tool to diagnose spinal tuberculosis and may be used to guide needle in percutaneous needle biopsy of paraspinous abscess. It is relatively less costly than MRI and is less time consuming.

4.3. Findings of MRI in CNS TB

Contrast-enhanced MRI is better than CT in detecting and assessing CNS tuberculosis[13-15]. MRI is superior to CT in identifying meningeal and parenchymal abnormalities, but due to its limited availability worldwide and essential need of general anesthesia in children suggest that it may have a limited impact on TBM diagnosis globally[16,17]. Magnetization transfer (MT) imaging is considered to be superior to conventional *spin echo* (SE) sequences for imaging abnormal meninges which appear hyperintense on pre contrast T1W MT images and show further enhancement on post contrast T1W images¹⁸. In addition, MT ratio quantification helps in predicting the etiology of meningitis[18,19]. Visibility of the inflamed meninges on precontrast T1W MT images with low MTR is specific for TBM, helping in differentiating it from other nontuberculous chronic meningeal infections [19]. Communicating type of hydrocephalus is more common complication in a patient of tubercular meningitis [20]. Periventricular hyperintensity on proton density and T2W images is due to the seepage of the CSF fluid across the white matter and usually suggests hydrocephalus under pressure, which is an indication for CSF diversion surgery to decompress the ventricular system[21]. Ischemic cerebral infarction resulting from the vascular occlusion is common sequelae of tuberculous arteritis. The middle cerebral and lenticulostriate arteries are most commonly affected [22, 23]. Diffusion-weighted imaging helps in the early detection of this complication [24]. Brain tuberculoma, a space-occupying mass of granulomatous tissue [25], forms a large percentage of intracranial mass lesions in the developing countries and is responsible for high morbidity and mortality. Tuberculomas may be single or multiple, and can be seen anywhere in the brain parenchyma [26].

A variable degree of vasogenic oedema surrounds the lesions, which is better appreciated on T2-weighted MR images. Enhancement of the granulomas on the post-gadolinium scans (Fig-3) improves their conspicuity and enables their differentiation from the adjacent vasogenic edema[27]. MR spectroscopy of the lesion shows lipid peak (Fig-4) in cases of Tubercular granulomatous lesions.

Tuberculomas are normally defined as low- or high-density, round or lobulated masses with irregular walls and show homogenous or ring enhancement after administering contrast [28]. The “target sign” (central nidus of calcification surrounded by a ring of enhancement) was once considered to be pathognomonic for tuberculoma, but this has recently been called into question [29, 30]. The radiographic presentation of tuberculomas depends largely on whether the lesion is noncaseating, caseating with a solid center, or caseating with a liquid center; the degree of edema surrounding the tuberculoma is thought to be inversely proportional to the age of the lesion. While new or enlarging tuberculoma may occur in some patients despite adequate antituberculosis therapy, the activity of tuberculoma can generally be assessed by the degree of contrast enhancement on follow-up CT or MRI studies[31]. Tuberculous brain abscess is a relatively rare condition constituting 4-7% of the total number of CNS TB cases in developing countries. According to the criteria of Whitener[32], tuberculous abscesses should show macroscopic evidence of abscess formation within the brain parenchyma and should offer histological confirmation that the abscess wall is composed of vascular granulation tissue containing both acute and chronic inflammatory cells and *M. tuberculosis*. MTR quantification from the rim of the abscess has helped in the differential diagnosis of tuberculous from pyogenic.

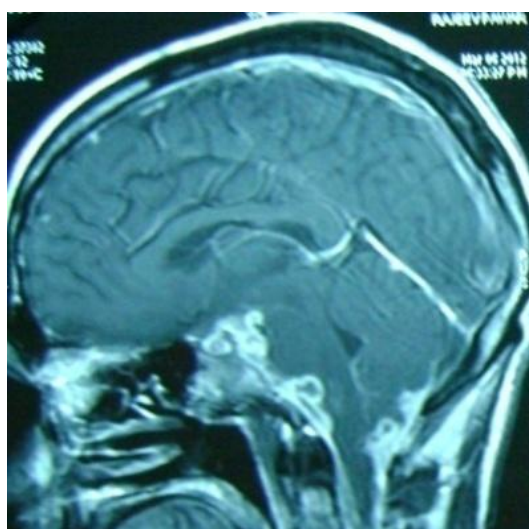


Fig. 3: Contrast enhanced MRI sagittal image showing basal exudates and tuberculoma.

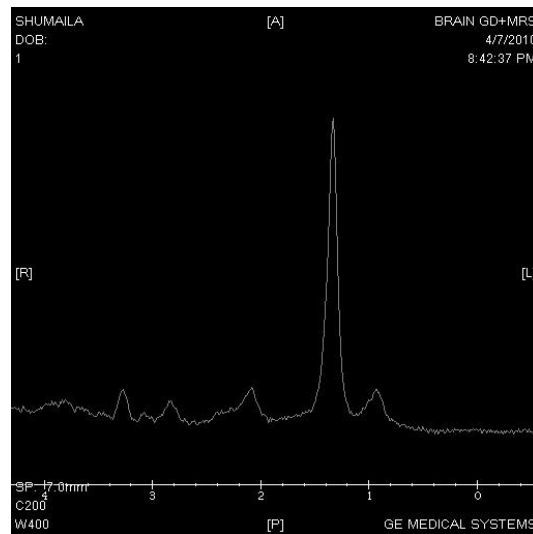


Fig. 4: MR spectroscopy of the lesion is showing lipid peak.

4.4 MRI of the Spine

A major advantage of MR imaging, compared with CT scan and plain radiography, is the higher sensitivity for detection of early inflammatory bone marrow changes and infiltrative end plate changes in the vertebra. MR imaging is mostly useful in delineating paravertebral, epidural, and intraosseous abscesses and in evaluating the extent of cord compression and the presence of intramedullary lesions¹¹. Because of its ability to detect marrow abnormalities before bony destruction, MRI is sensitive for the early detection of tuberculous spondylitis, even in patients with normal radiographs. Multiplanar capability, superior tissue contrast, ability to detect skip lesions, understanding the details of bony and soft tissue involvement, extent of extradural compression, presence or absence of meningeal involvement, cord changes etc. make MR imaging the modality of first choice in the evaluation and follow-up of tubercular spine[12,32]. The lack of risk of exposure to ionizing radiation makes it a safe investigation modality. MR imaging of vertebral tuberculous osteomyelitis shows low signal on T1-weighted images (Fig.5. A and B) and high signal on T2-weighted images in the endplate, narrowing of the disc, paraspinal and epidural abscesses, anterior scalloping, collapse of the vertebral bodies and abnormal signal involving multiple vertebral segments. Signal intensity changes may also be seen in the pedicle, laminae and synovium of articular facet joints. It may be associated with gibbus or kyphotic deformity. Intradural extramedullary tuberculoma is rare. Contrast MRI may delineate the lesion. For spinal arachnoiditis, MRI is the modality of choice as it delineates leptomeningeal disease better. MRI features include CSF loculation and obliteration of the spinal subarachnoid space with a loss of outline of the spinal cord in the cervicothoracic spine and matting of the nerve roots in the lumbar region.

Sometimes, patients who appear normal on unenhanced MRI images may show nodular, thick, linear, intradural enhancement, often completely filling the subarachnoid space on postcontrast images. In chronic stages of the disease, the postcontrast images may not show any enhancement even when unenhanced images show signs of arachnoiditis. Spinal cord involvement in the form of infarction and syringomyelia may occur as a complication of arachnoiditis. Parenchymal TB myelitis and tuberculoma formation may also occur. Syringomyelia is seen as cord cavitation that typically demonstrates CSF intensity on T1W and T2W images but does not enhance on postcontrast images[33].

5 Conclusion

The diagnosis of CNS tuberculosis, in clinical setting, is often not possible through microbiological, serologic and histopathological investigations. The radiological investigations help in starting the empirical tubercular therapy under these circumstances. Moreover, radiological investigations guide the continuation or change of the anti-tubercular regimen in early follow up of the patients. In some cases X-Ray Chest postero-anterior view may reveal evidence of tubercular etiology and so it should be done for all the patients of CNS TB undergoing neurosurgical procedures. Plain radiography of the spine may demonstrate the features suggestive tuberculous spondylodiscitis. Percutaneous CT guided needle biopsy is another tool to diagnose etiology of paraspinal abscess. CT scan is relatively less costly and less time consuming than MRI. It can be done whenever MRI is contraindicated. MR spectroscopy, contrast-enhanced MRI with magnetization transfer and MTR are better to CT in detecting and assessing CNS tuberculosis. Multiplanar

capability, superior tissue contrast, ability to detect skip lesions, understanding the details of bony and soft tissue involvement, extent of extradural compression, presence or absence of meningeal involvement, cord changes etc. make MR imaging the modality of first choice in the evaluation and follow-up of tubercular spine (Fig.6.A and B) spinal arachnoiditis and intramedullary lesions.

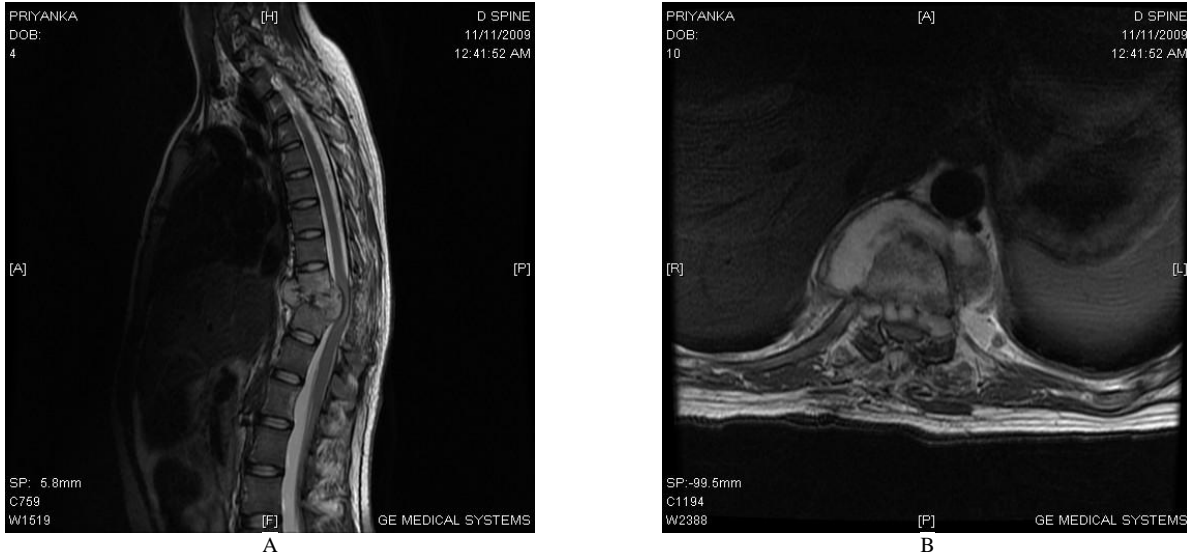


Fig. 5. A & B : MRI Thoracolumbar spine showing collapse of the vertebra and compression of the spinal cord due to granulation tissue in the T2W2 sagittal view , and axial views

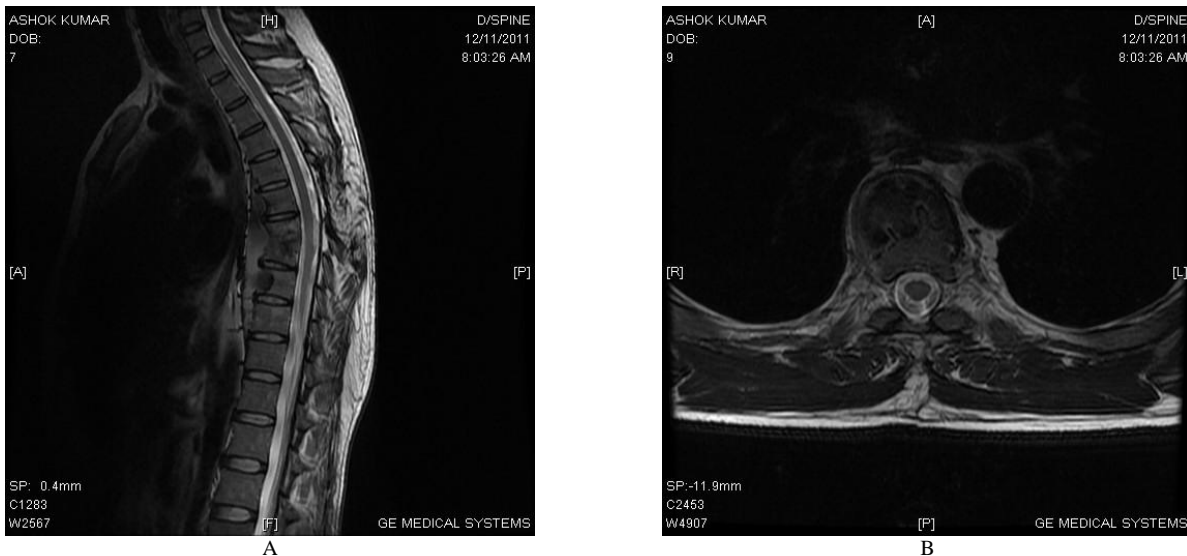


Fig. 6: A & B: Post operative follow up MRI Thoracolumbar spine T2W2 sagittal and axial views showing fusion of the adjoining vertebrae . Although granulation tissue is still present, it is confined anterior to the vertebral body, so there is no compression over the spinal cord leading to complete neurological recovery of the patient.

References

- [1] A Cherian, and S V Thomas. Central nervous system tuberculosis cases. African Health Sciences, 11(1), (2011), 116 – 127.
- [2] R. Trivedi, S. Saksena; R.K Gupta. Magnetic resonance imaging in central nervous system tuberculosis. Indian Journal Radiological Images. 19, (2009), 256-65.
- [3] N.I Girgis, Y. Sultan, Z. Farid, M.M. Mansour, M. W. Erian, L.S. Hanna, Tuberculosis meningitis, Abbassia Fever Hospital-Naval Medical Research Unit No. 3.Cairo, Egypt, from 1976 to 1996. American Journal of Tropical Medicine and Hygiene. 58(1), (1998), 28-34.
- [4] Z. I. Malik,; O. Ishtiaq, N. H. Shah, F. Anwer, H. Z. Baqai . Analysis and outcome of 30 patients with Tuberculous Meningitis. Pakistan Journal of Medical Research, Vol.41 No.4,(2002), 137-141.
- [5] K. Venugopal, P.R. Sreelatha, S. Philip, V. Kumar. Treatment outcome of neurotuberculosis patients put on DOTS--an observation study from the field. Indian J Tuberc. 55, (2008), 199-202

- [6] V.K.S. Gautam, S. Khurana and R. Singh. Primary Calvarial Tuberculosis (PCT) presenting as cold abscess of the scalp: A report of two cases. *IOSR Journal of Dental and Medical Sciences*, Volume 4, Issue 4, (2013), 14-17.
- [7] J. Ahmadi, A. Bajaj, S. Destian, H.D. Segall, C. S. Zee. Spinal tuberculosis: atypical observations at MR imaging. *Radiology*, 189 (1993), 489-493.
- [8] F. Maiuri., G. Iaconetta., B. Gallicchio., A. Manto, F. Brigantti. Spondylodiscitis. Clinical and magnetic resonance diagnosis. *Spine*. 22, (1997), 1741-1746.
- [9] E.Pertuiset, J. Beaudreuil, F. Lioté. Spinal tuberculosis in adults. A study of 103 cases in a developed country, 1980-1994. *Medicine*, 78, (1999), 309-320.
- [10] S.L. Moore, M. Rafii. Imaging of musculoskeletal and spinal tuberculosis. *Radiol Clin North America*, 39, (2001), 329-342.
- [11] A.I. De Backer, K.J. Mortelé, I.J. Vanschoubroeck, D. Deeren, F.M. Vanhoenacker, B.L. De Keulenaer, P. Bomans, M.M. Kockx. Tuberculosis of the spine: CT and MR imaging features. *JBR-BTR*, 88 (2) (2005), 92-97.
- [12] R. Kumar Spinal tuberculosis: with reference to the children of northern India. *Childs Nerv Syst*. Jan, 21(1), (2005), 19-26.
- [13] S. Przybojewski, S. Andronikou, and J. Wilmshurst. Objective CT criteria to determine the presence of abnormal basal enhancement in children with suspected tuberculous meningitis. *Pediatric Radiology*. 36: (2006), 687-696.
- [14] J. R. Jinkins, R. Gupta, K. H. Chang, and J. Rodriguez-Carbajal. MR imaging of central nervous system tuberculosis. *Radiol. Clin. N. Am.*33, (1995), 771-786.
- [15] F. Kioumeh, M. R. Dadsetan, S. A. Rooholamini, and A. Au. Central nervous system tuberculosis: MRI. *Neuroradiology*. 36, (1994), 93-96.
- [16] H. Offenbacher, F. Fazekas, R. Schmidt, R. Kleinert, F. Payer, G. Kleinert, and H. Lechner.. MRI in tuberculous meningoencephalitis: report of four cases and review of the neuroimaging literature. *J. Neurol*. 238, (1991), 340-344.
- [17] S. Andronikou, and N. Wieselthaler.. Modern imaging of tuberculosis in children: thoracic, central nervous system and abdominal tuberculosis. *Pediatr. Radiol*. 34, (2004), 861-875.
- [18] R.K. Gupta, M.K. Kathuria, S. Pradhan. Magnetization transfer MR imaging in CNS tuberculosis. *AJNR Am J Neuroradiol*.20,(1999),867-75.
- [19] R. Gupta. Magnetization transfer MR imaging in central nervous system infections. *Indian Journal Radiological Imaging*.;12,(2002), 51-58.
- [20] P. Kamra, R. Azad, K.N. Prasad, S. Jha, S. Pradhan, R.K. Gupta. Infectious meningitis: prospective evaluation with magnetization transfer MRI. *British Journal of Radiology*, 77, (2004), 387-94.
- [21] P.N. Tandon, R. Bhatia, S. Bhargava. "Tuberculous meningitis" In: Vinken PJ, Bruyn GW, Klawans HZ, editors. *Handbook of Clinical Neurology*. Vol 8. Amsterdam: Elsevier; 1988, 196-226.
- [22] I. Singh, M. Haris, M. Husain, N. Husain, M Rastogi, R.K. Gupta. Role of endoscopic third ventriculostomy in patients with communicating hydrocephalus: an evaluation by MR ventriculography. *Neurosurgery Review*, 31,(2008), 319-325.
- [23] D.K. Dastur, V.S. Lalitha, P.M. Udani, U. Parekh. The brain and meninges in tuberculous meningitis-gross pathology in 100 cases and pathogenesis. *Neurol India*.18,(1970),86-100.
- [24] R.K. Gupta, S. Gupta, D. Singh, B. Sharma, A. Kohli, R.B. Gujral. MR imaging and angiography in tuberculous meningitis. *Neuroradiology*. 36, (1994), 87-92.
- [25] R. Shukla, A. Abbas, P .Kumar, R.K. Gupta, S. Jha, K.N. Prasad. Evaluation of cerebral infarction in tuberculous meningitis by diffusion weighted imaging. *J Infect*. 57,(2008), 298-306.
- [26] P.N. Tandon, S.N. Pathak. Tuberculosis of the central nervous system. In: Spillane JD, editor. *In Tropical Neurology*. New York: Oxford University Press; (1973), 37-62.
- [27] R.K. Gupta, R.B. Lufkin. MR imaging and spectroscopy of central nervous system infection; in *Tuberculosis and other non-tuberculous bacterial granulomatous infection*. New York: Kluwer Academic, Plenum Publishers, (2001), 95-145
- [28] J.L.S. Khoo, K.Y. Lau, C.M. Cheung, T.H. Tsoi. Central Nervous System Tuberculosis. *J HK Coll Radiol*, 6, (2003), 217-228
- [29] M. K. Katti, Pathogenesis, diagnosis, treatment, and outcome aspects of cerebral tuberculosis. *Med. Sci. Monit*. 10, (2004), RA215-RA229.
- [30] A. Bernaerts, F. M. Vanhoenacker, P. M. Parizel, J. W. Van Goethem, R. Van Altena, A. Laridon, J. De Roeck, V. Coeman, and A. M. De Schepper.. Tuberculosis of the central nervous system: overview of neuroradiological findings. *Eur. Radiol*. 13, (2003), 1876-1890.
- [31] C. Tayfun, T. Üçöz, M. Taşar, et al. Diagnostic value of MRI intuberculous meningitis. *Eur Radiol*, 6, (1996), 380-386.
- [32] S. E. Berning, T. A. Cherry, and M. D. Iseman. Novel treatment of meningitis caused by multidrug-resistant *Mycobacterium tuberculosis* with intrathecal levofloxacin and amikacin: case report. *Clin. Infect. Dis*. 32, (2001), 643-646.
- [33] D.R. Whitener. Tuberculous brain abscess. Report of a case and review of the literature. *Arch Neurol*.; 35,(1978), 148-85.