

Florid Cemento-Osseous dysplasia - A hidden inquest

Dathar Sahithi ^{1*}, Sudhakara Reddy ², Ch. Sai Kiran ³, Tatapudi. Ramesh ⁴, N.Rajesh ⁵, Divya Teja ¹

¹ Post graduate student, Department of Oral medicine and Radiology, Vishnu Dental College
² Professor and Head of Department of Oral medicine and Radiology, Vishnu Dental College
³ Assistant Professor, Department of Oral medicine and Radiology, St. Josephs Dental College
⁴ Professor, Department of Oral medicine and Radiology, Vishnu Dental College
⁵ MDS, Department of Oral medicine and Radiology, Vishnu Dental College
*Corresponding author E-mail: sahithi.dathar9@gmail.com

Abstract

Florid cemento-osseous dysplasia (FCOD) is a rare distinguishable condition that characteristically affects the jaws of middle aged women. It is usually symmetrical on both sides and manifests radiographically as diffuse, lobulated multiple sclerotic radio-opacities involving all the quadrants of the jaws. The lesion is mostly benign and requires no treatment unless the patient is symptomatic. For the asymptomatic patient the best management advisable is regular recall checkups and reinforcement of good oral hygiene. Herewith, we are reporting one such rare entity of a 37 year old female patient.

Keywords: Florid Cemento-Osseous Dysplasia; Fibro-Osseous Lesion.

1. Introduction

Cemento-Osseous Dysplasia refers to the benign condition of the jaws and is known to originate either from the periodontal ligament tissues or from the fibroblasts (Dagistan et al. 2007). World Health Organization in 2005 has classified Cemento-Osseous Dysplasias (CODs) into periapical (surrounds the apical region of teeth), florid (sclerotic symmetrical masses), and focal (single lesion) CODs (Dagistan et al. 2007, Rao et al. 2011).

Florid cemento-osseous dysplasia (FCOD) was first described by Melrose et al in 1976 (Lawal et al.2011). It is categorised under fibro-osseous lesions, which has more of female predilection and is commonly seen affecting the middle age group (Dagistan et al. 2007, Shah et al. 2011, Kutluay et al. 2013). It is a rare disease, observed to be markedly exuberant and has a striking tendency to involve all the four quadrants of the jaws symmetrically (Lawal et al.2011, Rao et al. 2011, Komali et al. 2012). The word “florid” was introduced to portray its wide spread and remarkable nature of the disease to occur in multiple quadrants of the jaws (Rao et al. 2011).

The patients with FCOD are usually asymptomatic and occasionally some patients present with dull pain associated with swelling, purulent discharge and formation of sequestrum (Rao et al. 2011). Radiographically, the lesions appear as multiple sclerotic masses evident in both the jaws, predominantly in the mandible than the maxilla. The diagnosis of FCOD is usually arrived on the basis of the characteristic radiographic appearance.

The asymptomatic patients are accidentally diagnosed when they are subjected to routine radiographic examination and they can be left untreated. The best management for such patients probably includes regular recall examinations with oral prophylaxis and reinforcement of good oral hygiene practices so as to control periodontal disease and further preclude the loss of teeth (Dagistan et al. 2007, Komali et al. 2012). This paper describes one such rare

case of a patient, who was diagnosed as FCOD based on its characteristic radiographic appearance.

2. Case report

A 37 year old female patient had reported to our outpatient department with a chief complaint of severe sensitivity of her teeth since 1 month. On general examination, all the vital signs were within the normal range and extra-oral examination revealed her face to be bilaterally symmetrical with no signs of swelling or disfigurement. Intraoral examination revealed mild generalized gingival recession and presence of decayed teeth. To evaluate the periodontal status of her teeth panoramic image and intraoral periapical radiographs were obtained. Radiographic examination of the panoramic image (figure 1) had revealed, multiple radiopaque sclerotic masses evident in both the jaws involving all the four quadrants. A well-defined radiopacity was evident in the anterior mandible region which is surrounded by an irregular radiolucent border. Periapical radiographs (figure2, 3) of the mandibular molar and premolar regions had revealed multiple mixed radiolucent-radiopaque lesions corresponding to the periapical areas of the teeth with intact lamina dura, at a level above the inferior alveolar canal. Biopsy was not mandatory for confirmation, as the diagnosis of the present condition is usually based on radiographic examination. Indeed, biopsy would aggravate the risk of infection and occasionally may lead to fracture of the jaws. Considering these characteristic radiographic features, we had arrived at a diagnosis of Florid Cemento-Osseous dysplasia. As the patient was asymptomatic, the best management employed was regular recall checkups with oral prophylaxis and patient was also emphasized on maintenance of good oral hygiene in order to control the periodontal disease.

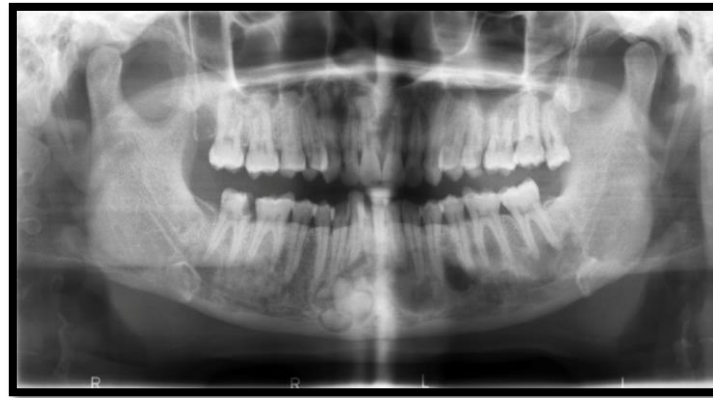

Fig. 1: Orthopantomogram Image Showing Multiple Ill-Defined Radiopacities in All the Quadrants of Both the Jaws and a Well Defined Radiopacity in the Anterior Mandible Surrounded by Irregular Radiolucent Border.

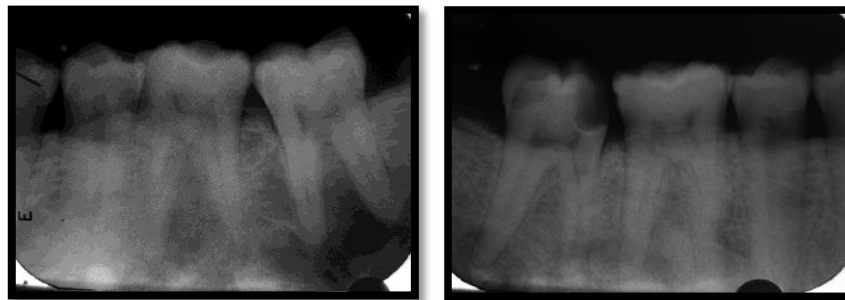


Fig. 2, 3: Intra Oral Periapical Radiographs Showing Multiple Mixed Radiolucent-Radiopaque Lesions Corresponding to the Periapical Areas of the Teeth with Intact Lamina Dura, at a Level Above the Inferior Alveolar Canal.

3. Discussion

Florid cemento-osseous dysplasia (FCOD) is a rare entity that has been interpreted as a dysplastic lesion or developmental anomaly arising from tooth-bearing areas (Dagistan et al. 2007) and can also occur as a sequel of focal cemento-osseous dysplasia (Bhandari et al. 2012). When patients are asymptomatic, conventional radiographs that exhibit multiquadrant diffuse radiopaque masses typically found in the tooth bearing areas of the jaws play an essential role in arriving at an appropriate diagnosis. The radiographic appearance, though not pathognomonic, is quite characteristic and very helpful in establishing the proper diagnosis (Kutluay et al. 2013).

It is basically a benign fibro-osseous lesion that has to be distinguished from other similar lesions like Chronic sclerosing osteomyelitis, Fibrous dysplasia, Ossifying fibroma, and Paget's disease based on combined clinical, radiographic, and histological features (Dagistan et al. 2007, Jong-Ki et al. 2013).

Chronic sclerosing osteomyelitis which is primarily an inflammatory condition of the jaws usually present with cyclic episodes of remissions and exacerbations, associated with unilateral pain, swelling and most often shows a single area of diffuse sclerosis containing small, ill-defined osteolytic areas (Paim et al. 2003, Dagistan et al. 2007). Whereas, florid cemento-osseous dysplasia is evident as lobulated opaque masses which is often surrounded by a characteristic radiolucent border and is evident in all the quadrants symmetrically.

FCOD neither shows the neoplastic nature like ossifying fibroma nor appear to be developmental nature like fibrous dysplasia. Monostotic fibrous dysplasia is commonly evident in the maxilla than the mandible (Gupta et al. 2011) and mostly unilateral (Cholakova et al. 2010), whereas FCOD broadens to involve all the four quadrants.

Paget's disease of jaws shows a marked tendency to involve the entire mandible or maxilla with loss of lamina dura and often reveals generalized hypercementosis with a characteristic cotton wool appearance radiographically, wherein FCOD occurs at a

level above the inferior alveolar canal. Moreover Paget's disease is often found to be polyostotic involving other bones such as spine, femur, skull, pelvis and sternum and laboratory investigations reveal increased levels of serum alkaline phosphatase enzyme (Dagistan et al. 2007, Rajkumar et al. 2011, and Shankar et al. 2013). No such biochemical variations and involvement of other bones were revealed in our present case.

It has been documented in literature that the diagnosis of florid cemento-osseous dysplasia can be relied on clinical and radiographic examination alone. Only if the patient is symptomatic, then reassurance of the diagnosis can be done by performing biopsy which can probably precipitate infection that becomes difficult to control without extensive surgical intervention. (Dagistan et al. 2007).

4. Conclusion

To summarize, Florid cemento-osseous dysplasia is seen as an unusual entity affecting the jaws. We have observed one such rare entity in the jaws of an asymptomatic patient and had diagnosed based on its unique radiographic features. Although the treatment is not mandatory for asymptomatic patients, periodic follow up is essential to prevent any unpredictable outcome in near future.

References

- [1] Bhandari R, Sandhu SV, Bansal H, Behl R, Bhullar RK. (2012) Focal cemento-osseous dysplasia masquerading as a residual cyst. *Contemp Clin Dent*; 3:60-62. <http://dx.doi.org/10.4103/0976-237X.95107>.
- [2] Cholakova R., P. Kanasirska, N. Kanasirski, IV. Chenchev, A. Dinkova. (2010). Fibrous dysplasia in the maxillo-mandibular region – Case report. *Journal of IMAB*; 6(4):10-13.
- [3] Dagistan S, Tozoglu U, Goregen M, Cakur B. (2007). Florid cemento-osseous dysplasia: A case report. *Med Oral Patol Oral Cir Bucal*; 12: 48-50.
- [4] Dagistan S, Goregen M, Cakur B, Miloglu O. (2007). Cemento-osseous dysplasias. *Rev. Clín. Pesq. Odontol*; 3 (1):43-49.

- [5] Gupta S, Umesh K, Warad NM, Ahmed S. (2011) Fibrous Dysplasia of Maxillary Bone: A Case Report. *Al Ame en J Med Sci*, 4 (1):92 -97.
- [6] Jong-Ki Huh, Su-Jung Shin. (2013). Misdiagnosis of florid cemento-osseous dysplasia leading to unnecessary root canal treatment: a case report. *Restor Dent Endod*; 38(3):160-166. <http://dx.doi.org/10.5395/rde.2013.38.3.160>.
- [7] Komali G, Vinitha KB, Mahesh Rao. (2012). Florid osseous dysplasia- a case report. *Int J Dent Case Reports*; 2(5): 42-46.
- [8] Kutluay Koklu H, Cankal DA, Bozkaya S, Ergun G, Barış E. (2013) florid cemento-osseous dysplasia: Report of a case documented with clinical, radiographic, biochemical and histological findings. *J Clin Exp Dent*; 5(1):e58-61. <http://dx.doi.org/10.4317/jced.50854>.
- [9] Lawal AO, Adisa AO, and Lasisi TJ. (2011). florid cemento-osseous dysplasia: a report of two cases seen at the university college hospital Ibadan. *Annals of Ibadan Postgraduate Medicine*; 9(1):45-47. <http://dx.doi.org/10.4314/aipm.v9i1.72435>.
- [10] Paim LB et al. (2003). Chronic recurrent multifocal osteomyelitis of the mandible. *J Pediatr (Rio J)*; 79 (5):467-70.
- [11] Rao KA, Shetty SR, Babu SG, Castelino RL. (2011) Co-Occurrence of Florid Cemento-Osseous Dysplasia and Simple Bone Cyst: a Case Report. *J Oral Maxillofac Res (Jul-Sep)*; 2 (3):1-8. <http://dx.doi.org/10.5037/jomr.2011.2305>.
- [12] Rajkumar GC, Ramesh B, Shashikala R, Manjunath. (2011). Paget's disease of Maxilla. *World Journal of Dentistry*, January-March; 2 (1):49-51.
- [13] Shah V, Soni N, Manjunatha BS, Kumar S.(2011) Florid cemento-osseous dysplasia – An Unusual entity. *Oral & Maxillofacial Pathology Journal*; 2 (2):161-164.
- [14] Shankar YU, Misra SR, Vineet DA, Baskaran P. (2013). Paget disease of bone: A classic case report. *Contemp Clin Dent*; 4: 227-30. <http://dx.doi.org/10.4103/0976-237X.114858>.