

A compressive survey on different image processing techniques to identify the brain tumor

K. Bhagavan^{1*}, Dr. S. Sagar Imambi¹, Dr. Shahana Bano¹

¹ Department of Computer Science and Engineering, Koneru Lakshmaiah Education Foundation, Vaddeswaram. Guntur Dist, AP

*Corresponding author E-mail: bhagavan@kluniversity.in

Abstract

Medical imaging technology has revolutionized health care over the past three decades allowing doctors to detect, cure and improve patient outcomes. Medicinal imaging makes picture of the internal organs, parts, tissues and bones for therapeutic examination and research purposes. It can likewise be utilized to think about elements of a few organs. X-ray and CT scanner are the two greatest after-effect of headway of imaging methods supplanting 2D procedures. X-ray is the standout amongst the most critical pre-processing ventures in tumor discovery. Magnetic resonance imaging (MRI) is really an imaging procedure in the restorative field. It is utilized as a part of radiology for imagining interior structures of the body and furthermore how they work. X-ray gives you the 3D picture of the inside bits of the body which enables the specialist to dissect the infection or tumor effortlessly though old imaging procedures like x-beam imaging gives you 2D pictures. In this paper we are introducing distinctive systems for distinguishing, preparing restorative pictures.

Keywords: Image Processing; Medical Imaging; X-Ray; Magnetic Resonance Imaging; X-Beam Imaging.

1. Introduction

Medicinal Imaging is a component used to make the visual portrayal of the inward parts of the body that is, a few organs or tissues primarily for clinical investigation, for example, to analyze or to treat infections. For better conclusion and treatment, the acquired pictures ought to be extremely powerful. Keeping in mind the end goal to acquire viable pictures, a restorative picture handling strategies assumes a key part in therapeutic, which includes different imaging modalities in light of the body parts which are under scrutiny. So as to improve the visual elucidation, the different picture handling strategies are utilized as a part of chain of command, for instance, picture upgrade goes before division, which will go before highlight extraction and determination. At last, the investigation of medicinal picture is performed keeping in mind the end goal to decide the anomalies introduce. Here fig-1 gives the means engaged with Brain tumor discovery utilizing MRI picture and Image preparing instruments.

1.1. Pre-processing

Inclusion of MRI cerebrum picture and sifting happens in pre-processing. X-ray imaging contains commotion, in any case, this clamour isn't that key so an average channel is utilized to smoothen the picture from a few channels. This smoothed picture is sent for next process. Normal channel is a simple and essential usage for smoothening of pictures.

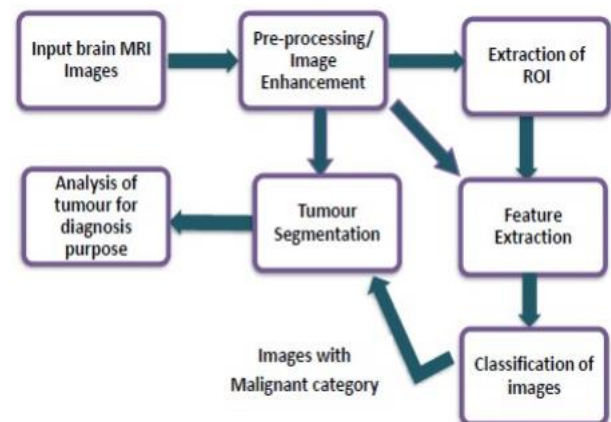


Fig. 1: Brain Tumour Detection Using MRI Image and Image Processing Mechanism.

1.2. Skull stripping

A standout amongst the most critical procedures in bio medicinal picture examination is skull stripping. Skull stripping is required for cerebrum picture investigation yet not for other organ examination like heart, lungs and so forth. Skull stripping is done before some other picture preparing. This procedure is utilized for end of all no brain tissues from the cerebrum. All the additional tissues, for example, skin, fat, and skull is expelled utilizing this procedure. There are different techniques for skull stripping. Skull stripping is one of the techniques in light of limit esteem which is utilized to expel the skull tissue. In this technique, edge estimation of skull tissues and that of typical mind tissues is resolved physically for each picture.

1.3. Segmentation of image

The Segmentation of pictures in this calculation is finished by watershed division. The procedure of watershed division is a slope based system. Diverse calculations can be utilized to register watershed methods. This is one of the calculations. Diverse watershed procedures can be utilized some of them are flooding, topographic separation, drop of water guideline, Inter-pixel and Topological watershed techniques. To control over the division, Marker controlled watershed division is utilized [3]. In marker controlled watershed division, sobel operation is utilized to unmistakable the edge of the protest [3].

1.4. Morphological operation

Morphological operations depend on non-straight operations which are identified with the state of other morphological highlights of the picture. These operations are utilized for twofold imaging as they rely upon the bury pixel includes and not on the numerical esteem. In this strategy, disintegration method is connected to recognize tumour. This operation deals with the procedure that, it first tests the state of a picture is as of now pre-characterized and makes inferences as though how the shape misses or fits the picture shapes.

Figure-1 shows the "Brain tumour detection using MRI image and Image processing mechanism" and it as follows at first we will take the MRI cerebrum pictures as a contribution to the mind pictures investigation, these sort of pictures contain clamour The essential undertaking of pre-handling is to enhance the nature of the MR pictures and make it in a shape suited for additionally preparing by human or machine vision framework. Furthermore, pre-handling enhances certain parameters of MR pictures, for example, enhancing the flag to-commotion proportion, upgrading the visual appearance of MR picture, expelling the immaterial clamour and undesired parts out of sight, smoothing the inward piece of the locale, and safeguarding its edges. A locale of intrigue (frequently abridged ROI), are tests inside an informational collection distinguished for a specific reason. The idea of a ROI is generally utilized as a part of numerous application territories. For instance, in therapeutic imaging, the limits of a tumour might be characterized on a picture or in a volume, to measure its size. The endocardial outskirts might be characterized on a picture, maybe amid various periods of the cardiovascular cycle, for instance, end-systole and end-diastole, to assess heart work. The division of the tainted cerebrum MR locales is accomplished through the accompanying strides: In the initial step, the pre-processed mind MR picture is changed over into a parallel picture with an edge for the cut-off of 128 being selected. The pixel esteems more prominent than the chose limit are mapped to white, while others are set apart as dark; because of this two, unique districts are conformed to the contaminated tumour tissues, which are edited out. In the second step, keeping in mind the end goal to dispose of white pixel, a disintegration task of morphology is utilized. At long last, the disintegrated district and the first picture are both separated into two equivalent locales and the dark pixel area removed from the dissolve task is considered a cerebrum MR picture cover. In this examination, Berkeley wavelet change is utilized for viable division of mind MR picture. It is the way toward gathering higher level data of a picture, for example, shape, surface, shading, and complexity. Actually, surface investigation is a critical parameter of human visual observation and machine learning framework. It is utilized viably to enhance the precision of finding framework by choosing noticeable highlights. At long last we go for diagnosing of the tumour with better understanding and better recognizable proof.

2. State-of-the art

J.J. Corso, et al. [7] proposed Bayesian model based division approach which is quicker contrasted with other best in class divi-

sion ways to deal with section GBM cerebrum tumour and edema. It was a novel approach of expanding Segmentation by Weighted Aggregation (SWA) calculation and consolidating model based affinities estimation which was sans show routinely. Their approach was completely robotized, quicker in execution and accomplished compar-atively great division exactness than few existing systems. About 70% division exactness was accomplished and a couple of disappointment cases were additionally detailed with extent of change [8].

Jan Kybic and Michael Unser (2003) together set forth an approach for picture enlistment. They introduced a calculation for quick versatile multidimensional power based picture enlistment with a parametric model of the misshapening, speaking to the distortion by a direct number of parameters.

The creators (Bentoutou et al 2005) offered a programmed picture enlistment for applications in remote detecting. In this paper an imaginative programmed satellite picture enlistment approach is anticipated. The procedure used the invariant relations between areas of a unique and a detected picture, separately. Their test comes about exhibited the strength and precision of the calculation. A novel approach for picture enrollment is depicted by Luciano Silva et al (2005). The approach tends to the range picture enrollment issue for sees having low cover which incorporates significant commotion.

Fluffy c-implies (FCM) bunching strategy has been broadly utilized for portioning therapeutic pictures. Bing, et al. displayed fluffy level set based computerized approach of fragmenting therapeutic pictures. After introductory divisions by FCM, controlling parameters of level sets are evaluated and it additionally advances to discover protest limits and results into strong division. It accomplished great division results to isolate WM, GM tissues in cerebrum MRI and tumour in CT check pictures [6], [25].

Bidirectional Associative Memory (BAM)- type Artificial Neural Network (ANN) based strategy for division and characterization of medicinal pictures, proposed by Sharma, et al. [23] performed great even in nearness of commotion and accomplished 100% characterization rate. In this strategy, just to select surface highlights, supervision is required, yet no preparation is required then after. The bigger size protest may increment computational time for division.

Khotanlou, et al. [14] proposed and analyzed two strategies for 3D cerebrum tumour division from MRI, one in view of fluffy and deformable models, and other in light of symmetry examination and deformable models. Likewise, the two techniques were contrasted and manual division and discovered equivalent outcomes. The primary technique in view of symmetry investigation indicated enhanced outcomes in division quality, while the other fluffy based strategy was speedier and unsupervised. Deformable models refined division by forcing spatial imperatives.

Khaissidi et al (2009) proposed a component based enrolment approach. A completely non administered philosophy committed to the quick enlistment of medicinal pictures that breaks down the estimation parameters in two stages: an identification of point highlight and a voting procedure is depicted in this paper.

Peng Wen (2008) proposed a powerful, quick and precise medicinal picture enrolment calculation utilizing focuses, form and bends. Nanthagopal, et al. [24] introduced surface component extraction technique in light of wavelet, division and characterization by SVM and Probabilistic Neural Network (PNN). The SVM announced most noteworthy order and division precision, superior to PNN, and was practically identical with the ground truth. The surface highlights in light of co-event and predominant run length enhanced division exactness. The confinement of the technique was that it was relevant to CT examine pictures just, and required new preparing amid new dataset [25]. k-Nearest Neighbour (kNN) classifier was utilized to portion white issue injury (WML) from cerebrum MRI pictures in [26]. The execution of kNN was enhanced by joining spatial tissue compose priors (TTPs), and by normalizing powers. Their technique revealed great outcomes with reference division. TTPs fragmented WML all the more precisely.

Demirhan, et al. [26] introduced Self-Organizing Map (SOM) and Learning Vector Quantization (LVQ) based strategy for dividing cerebrum MRI pictures into dark issue, white issue and other foundation districts. LVQ was utilized to advance and adjust weights of SOM. Technique announced great outcomes for dim issue, while revealed normal outcomes in sectioning white mater. Various Gaussian segments, when used to speak to numerous mind tissues, created smooth division.

Greenspan, et al. [27] proposed compelled Gaussian blend display with different Gaussian segments for portioning cerebrum MRI pictures. Desire Maximization (EM) was utilized to learn parameters of GMM. The outcomes were better and equivalent with alternate calculations like KVL calculation, Marroquin calculation and other detailed outcomes. Their strategy was totally computerized and unsupervised approach where enlistment and chart book are not required. The outcomes were analysed in view of Dice metric, Tanimoto metric and the mean outright surface separation metric. It can be utilized as another option to the MRF show.

A generative probabilistic model for sectioning cerebrum tumor has been utilized as a part of it. The proposed robotized approach divided tumor in view of earlier chart book to contemplate qualities of solid tissues and tumors from multimodal pictures. The strategy performed superior to mul-tivariate EM technique for division. The utilization of MRF to join spatial earlier aided in recognizing tumor with comparable attributes.

Rajendran, et al. [22] proposed fluffy bunching and deformable models based mind tumor division. In their work, starting division was performed utilizing fluffy bunching which gave beginning shape and last forms were resolved utilizing deformable model utilizing GVF which gave correct tumor limit. This strategy was discovered precise and vigorous in division of cerebrum tumors [23].

Senthil Periaswamy and Hany Farid (2005) talked about a broadly useful enlistment calculation for enrolling a scope of engineered and clinical therapeutic pictures and volumes including an unequivocal model that at the same time fragments and registers pictures with incomplete or missing information. The assessment of nonsampled contourlet change (NSCT) and MI based enlistment of highlight focuses and interpretation parameters that are ascertained by utilizing molecule swarm enhancement (PSO) for 2-D MR monomodal enrollment (Al-Azzawi et al 2010) created absolutely exact execution.

Li et al. displayed cross breed strategy for Watershed and level set for portioning MRI pictures [21]. In this work, introductory division has been performed in view of watershed technique and after that level set strategy is connected to recognize limits of items from beginning sections. This technique was discovered quick and productive. In this strategy, district limits were effortlessly distinguished by level set technique as their edges were at that point recognized by watershed technique. Their outcomes have been discovered superior to anything C-V show which is critical area based division strategy.

Dvorak, et al. [19]. They could isolate edema of various size, shape and at various area from FLAIR MRI pictures. Edema was recognized in view of examination of histogram of pieces from left and right halves of the globe. Asymmetry between histogram of squares was thought about in light of Bhattacharya coefficient and most topsy-turvy piece is relied upon to contain edema [10].

With same rule of mind symmetry, Shah, et al. [28] introduced a quick bouncing box way to deal with identify tumor or edema. In this technique, normal dice coefficient accomplished are 0.57 and 0.52. They presumed that to discover correct limits of tumor, different calculations should be connected.

3. Conclusion

Medical imaging innovation has changed human services in the course of recent decades enabling specialists to recognize, cure and enhance quiet results. Therapeutic imaging makes picture of the internal organs, parts, tissues and bones for restorative investi-

gation and research purposes. It can likewise be utilized to think about elements of a few organs. X-ray and CT scanner are the two greatest after effect of progression of imaging systems supplanting 2D methods. X-ray is the standout amongst the most imperative preprocessing ventures in tumor recognition. Attractive reverberation imaging (MRI) is really an imaging strategy in the medicinal field. It is utilized as a part of radiology for envisioning inner structures of the body and furthermore how they work. X-ray gives you the 3D picture of the inside bits of the body which enables the specialist to investigate the illness or tumor effectively though old imaging strategies like x-beam imaging gives you 2D pictures. This paper gives the point by point audit of various mind picture investigation methods and their preferences and hindrances. As of our future work we will propose a novel strategy which neatly identifies the mind tumour.

References

- [1] T. Logeswari and M. Karnan, "An improved implementation of brain tumor detection using segmentation based on soft computing," *Journal of Cancer Research and Experimental Oncology*, vol. 2, no. 1, pp. 006–014, 2009.
- [2] S. Bauer, R. Wiest, L.-P. Nolte, and M. Reyes, "A survey of mri-based medical image analysis for brain tumor studies," *Physics in medicine and biology*, vol. 58, no. 13, p. R97, 2013.
- [3] P. Kleihues and B. W. Stewart, "World cancer report," 2003.
- [4] N. Gordillo, E. Montseny, and P. Sobrevilla, "State of the art survey on mri brain tumor segmentation," *Magnetic resonance imaging*, vol. 31, no. 8, pp. 1426–1438, 2013.
- [5] S. Roy, S. Nag, I. K. Maitra, and S. K. Bandyopadhyay, "A review on automated brain tumor detection and segmentation from mri of brain," *arXiv preprint arXiv:1312.6150*, 2013.
- [6] S. Yousefi, R. Azmi, and M. Zahedi, "Brain tissue segmentation in mr images based on a hybrid of mrf and social algorithms," *Medical image analysis*, vol. 16, no. 4, pp. 840–848, 2012.
- [7] J. J. Corso, E. Sharon, S. Dube, S. El-Saden, U. Sinha, and A. Yuille, "Efficient multilevel brain tumor segmentation with integrated bayesian model classification," *Medical Imaging, IEEE Transactions on*, vol. 27, no. 5, pp. 629–640, 2008.
- [8] M. A. Balafar, A. R. Ramli, M. I. Saripan, and S. Mashohor, "Review of brain mri image segmentation methods," *Artificial Intelligence Review*, vol. 33, no. 3, pp. 261–274, 2010. 113
- [9] "What you need to know about brain tumors, U.S. National Institute of Health- National Cancer Institute." <http://www.cancer.gov/cancertopics/wyntk/brain/allpages>, 2003. [Online; accessed Mar.2003].
- [10] J. Mikulka and E. Gescheidtova, "An improved segmentation of brain tumor, edema and necrosis," in *PIERS Proceedings*, pp. 25–28, 2013.
- [11] "MRI brain datasets available on BRATS 2012." <http://www2.imm.dtu.dk/projects/BRATS2012/>.
- [12] M. Balafar, "Gaussian mixture model based segmentation methods for brain mri images," *Artificial Intelligence Review*, vol. 41, no. 3, pp. 429–439, 2014.
- [13] B. Caldairou, N. Passat, P. A. Habas, C. Studholme, and F. Rousseau, "A non-local fuzzy segmentation method: application to brain mri," *Pattern Recognition*, vol. 44, no. 9, pp. 1916–1927, 2011.
- [14] H. Khotanlou, O. Colliot, J. Atif, and I. Bloch, "3d brain tumor segmentation in mri using fuzzy classification, symmetry analysis and spatially constrained deformable models," *Fuzzy Sets and Systems*, vol. 160, no. 10, pp. 1457–1473, 2009.
- [15] X. Lladó, A. Oliver, M. Cabezas, J. Freixenet, J. C. Vilanova, A. Quiles, L. Valls, L. Ramió-Torrentà, and À. Rovira, "Segmentation of multiple sclerosis lesions in brain mri: a review of automated approaches," *Information Sciences*, vol. 186, no. 1, pp. 164–185, 2012.
- [16] A. Kharrat, N. Benamrane, M. Ben Messaoud, and M. Abid, "Detection of brain tumor in medical images," in *Signals, Circuits and Systems (SCS)*, 2009 3rd International Conference on, pp. 1–6, IEEE, 2009.
- [17] M. Martín-Fernández, C. Alberola-Lopez, J. Ruiz-Alzola, and C.-F. Westin, "Sequential anisotropic wiener filtering applied to 3d mri data," *Magnetic resonance imaging*, vol. 25, no. 2, pp. 278–292, 2007.
- [18] V. SA and K. Narayanankutty B, "Image enhancement of medical images using gabor filterbank on hexagonal sampled grids," *World Academy of Science, Engineering and Technol- Saurabh A Shah*

- 114 ogy, *International Journal of Electrical, Computer, Energetic, Electronic and Communication Engineering*, vol. 4, no. 5, pp. 853–858, 2010.
- [19] P. Dvorak, K. Bartusek, and W. Kropatsch, “Automated segmentation of brain tumoredema in flair mri using symmetry and thresholding,” in *Progress in Electromagnetics Research Symposium*, pp. 936–939, 2013.
- [20] M. Nixon, *Feature extraction & image processing*. Academic Press, 2008.
- [21] B. N. Li, C. K. Chui, S. Chang, and S. H. Ong, “Integrating spatial fuzzy clustering with level set methods for automated medical image segmentation,” *Computers in biology and medicine*, vol. 41, no. 1, pp. 1–10, 2011.
- [22] A. Rajendran and R. Dhanasekaran, “Fuzzy clustering and deformable model for tumor segmentation on mri brain image: A combined approach,” *Procedia Engineering*, vol. 30, pp. 327–333, 2012.
- [23] N. Sharma, L. M. Aggarwal, et al., “Automated medical image segmentation techniques,” *Journal of medical physics*, vol. 35, no. 1, p. 3, 2010.
- [24] A. P. Nanthagopal and R. Sukanesh, “Wavelet statistical texture features-based segmentation and classification of brain computed tomography images,” *Image Processing, IET*, vol. 7, no. 1, pp. 25–32, 2013.
- [25] M. D. Steenwijk, P. J. Pouwels, M. Daams, J. W. van Dalen, M. W. Caan, E. Richard, F. Barkhof, and H. Vrenken, “Accurate white matter lesion segmentation by k nearest neighbor classification with tissue type priors (knn-ttps),” *NeuroImage: Clinical*, vol. 3, pp. 462–469, 2013.
- [26] A. Demirhan and I. Güler, “Combining stationary wavelet transform and self-organizing maps for brain mr image segmentation,” *Engineering Applications of Artificial Intelligence*, vol. 24, no. 2, pp. 358–367, 2011.
- [27] H. Greenspan, A. Ruf, and J. Goldberger, “Constrained gaussian mixture model framework for automatic segmentation of mr brain images,” *Medical Imaging, IEEE Transactions on*, vol. 25, no. 9, pp. 1233–1245, 2006.
- [28] S. A. Shah and N. C. Chauhan, “An automated approach for segmentation of brain mr images using gaussian mixture model based hidden markov random field with expectation maximization,” *Journal of Biomedical Engineering and Medical Imaging*, vol. 2, no. 4, p. 57, 2015.
- [29] B. H. Menze, K. Van Leemput, D. Lashkari, M.-A. Weber, N. Ayache, and P. Golland, “A generative model for brain tumor segmentation in multi-modal images,” in *Medical Image Computing and Computer-Assisted Intervention—MICCAI 2010*, pp. 151–159, Springer, 2010.
- [30] J. Sachdeva, V. Kumar, I. Gupta, N. Khandelwal, and C. K. Ahuja, “A novel content based active contour model for brain tumor segmentation,” *Magnetic resonance imaging*, vol. 30, no. 5, pp. 694–715, 2012.